Figura 2: Área de Fibrosis (con sustracción de espacio perivascular)
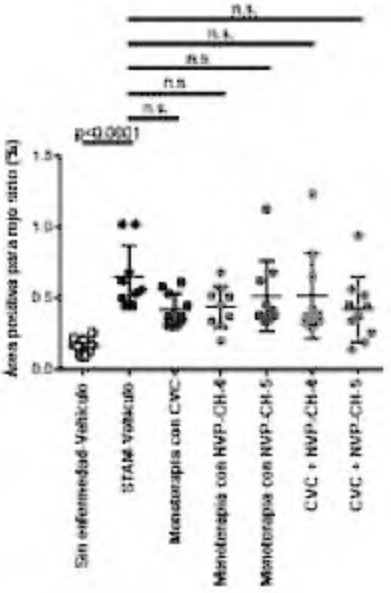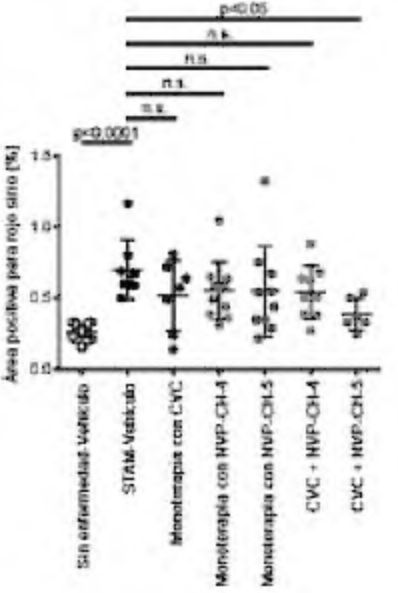
Estudio 1 y Estudio 2